

L R I

Limbal
Relaxing
Incisions

James P. Gills Nomogram for Limbal Relaxing Incisions with Cataract Surgery

Limbal relaxing incisions (LRI's) have been found to be effective for the correction of astigmatism. LRI's can correct astigmatism up to 8 diopters; but routinely we reserve the use of LRI's for 0.5 to 4 diopters of astigmatism. They can be performed at the time of cataract surgery or as an independent procedure.

Compared to corneal relaxing incisions (CRI's), LRI's are a weaker corrective procedure; however, LRI's produce less postoperative glare, less discomfort, and the incisions heal faster. Unlike CRI's, making the incision at the limbus preserves the perfect optical qualities of the cornea. LRI's are a more forgiving procedure and surgeons often get excellent results – even with their early cases.

The forgiving nature of the LRI is due to the placement and length of the incision. Placing the incision precisely on axis is not as critical because the incision is 9 mm in length. Since the incision produces less effect than CRI's, significant overcorrections are rare. The amount, axis, and symmetry of the corneal cylinder are determined by keratometry and topography.

The refractive cylinder is not considered in phakic patients. The surgical keratometer is used to confirm results. I find the surgical keratometer the most important instrument to identify the steep axis.

LRI's are made using a DSP Gills Pop-Up micrometer knife. They are placed in the steep axis at the limbus just anterior to the Palisades of Vogt. A 6 mm incision is required for each diopter of astigmatism up to 2 diopters. To correct between 2-3 diopters, LRI's of 8 mm in length are used.

We generally use the scleral limbal corneal incision (SLIC) incision for with-the-rule (WTR) cases and cases with low against-the-rule (ATR) astigmatism. When using the SLIC incision in conjunction with ATR astigmatism, the LRI can be moved slightly into the cornea or alternatively, the LRI could be placed opposite the SLIC. For higher amounts of ATR astigmatism (requiring 2 LRI's), the Langerman Hinge is used in conjunction with the LRI. For WTR, or oblique astigmatism, the SLIC is made temporally and the LRI(s) are placed at the steep axis. See Figures below:

Figure 1a

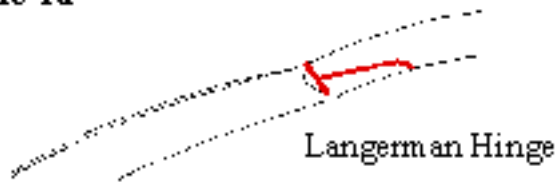


Figure 1b

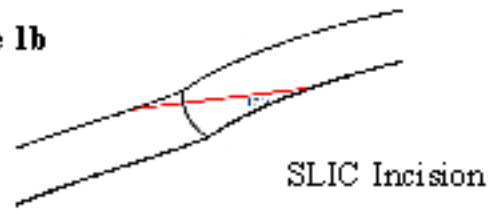

Figure 2 Against-The-Rule

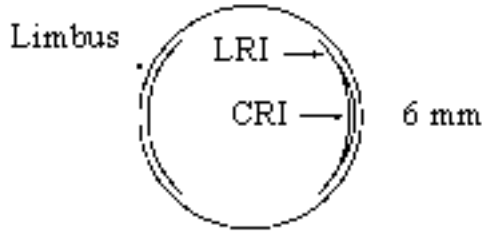
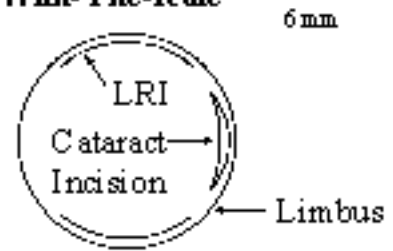


Figure 3 With-The-Rule



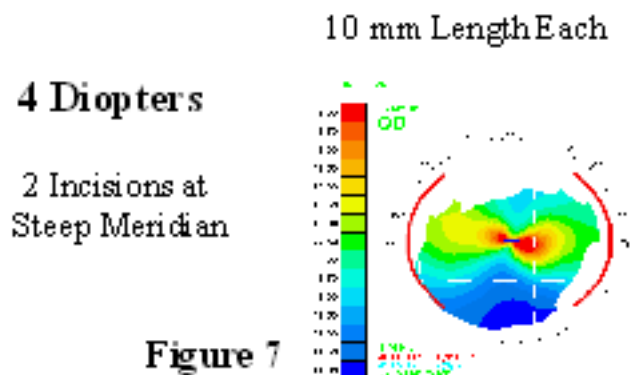

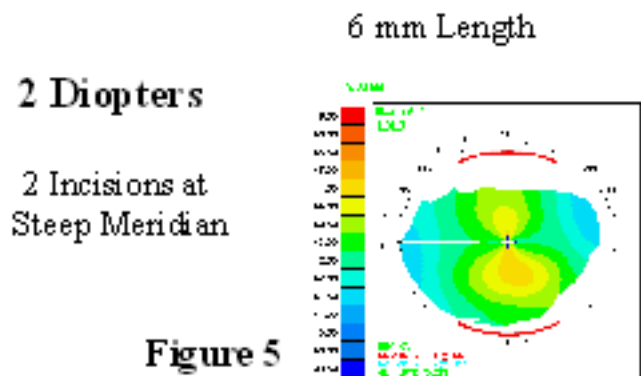

The placement of the LRI should be customized to the topography. In cases of asymmetric astigmatism, the LRI in the steepest axis can be elongated slightly and shortened the same amount in the flatter of the two steep axes. Paired LRI's do not have to be made in the same meridian. If the topography reveals non-orthogonal astigmatism, each of the LRI's are placed at the steepest portion of the bow tie. (See Nomogram Figure 6).

Overcorrections are unusual – it is much more likely for undercorrection to occur. In the case of an overcorrection, the LRI can be sutured without creating any irregular astigmatism. LRI's lend themselves to enhancement depending on the situation. For example, if an undercorrection occurs with a single 6 mm LRI, it could be extended to 8 mm, or a second LRI could be performed.

Correction of Astigmatism with Cataract Surgery

The following nomogram was developed for limbal relaxing incisions to correct astigmatism at the time of surgery. This nomogram applies to patients older than 73 years of age. Patients younger than 73 require longer incisions to achieve the same effect.

Limbal Relaxing Incisions for 1 – 4 Diopters of Astigmatism



Blade setting: 600 microns for most patients
(Exception: Blade setting of 500 microns for patients over 80 and for those with corneo-scleral thinning)

Relaxing Incision for > 4 D of Astigmatism

Incisions	Blade Settings	Length	Optical Zone	# of Incisions
LRI	600 microns	9 mm	at limbus	2
CRI (for the residual astig.)	99% depth (pachymetry)	2 mm for every D over 4D	8 mm	based on correction desired over 4D

Limbal relaxing incisions and CRI's for > 4 diopters of astigmatism

For astigmatism greater than 4 diopters, LRI's are combined with CRI's in order to attain adequate correction. The limbal relaxing incisions are used to correct the first 4 diopters. The remaining astigmatism over 4 diopters is corrected by the corneal relaxing incisions.

The preceding nomograms constitute a “no fuss” approach to correcting astigmatism; however, it is always important to plan your strategy around corneal topography, keratometry, and surgical keratometry.

Correcting Astigmatism in the Pseudophakic Patient

These same nomograms used for phakic patients are applied to pseudophakes. However, the axis and amount of astigmatism in pseudophakic patients are determined by the refraction only. Topography is used to determine the symmetry of the astigmatism.

**"This is a practical, no fuss and forgiving approach to correcting astigmatism."
--James P. Gills, MD**